BOA TRAVELLING FELLOWSHIP REPORT
ZIMMERBIOMET-ADULT RECONSTRUCTIVE IN HIPS AND KNEES

MR TOSAN OKORO. JUNE 2016

EXECUTIVE SUMMARY

I spent 2 weeks in May 2016 as a BOA travelling fellow at the Endo-Klinik in Hamburg, Germany with my primary interest being the management of soft tissue and bony defects in the acetabulum and femur. A majority of such defects at the Endo-Klinik were as a result of prosthetic joint infection (PJI) and the Endo-Klinik has pioneered the single stage revision as the management modality of choice for the majority of patients with PJI. With regards to acetabular defects, I was able to observe different strategies of dealing with these, from the use of impaction bone grafting with tantalum augments and a cemented cup to use of a custom made implant in a case of severe acetabular bone loss with protrusio. My visit has highlighted the benefits of the multidisciplinary approach in the practice of single stage revision for PJI (uncommon in the UK), with close liaison with microbiology essential. The usefulness of close links between orthopaedic surgeons and the implant industry was also a take home point as development of appropriate implants to deal with a variety of defects has been perfected over a period time. The visit also highlighted the benefits of having a specialist centre to deal with PJIs, as there was a consistency in the management of these patients, which in turn produced consistently good outcomes (10% risk of re-infection at 10 years). I am grateful for the opportunity afforded me by this fellowship.

REPORT

I spent 2 weeks in May 2016 as a BOA travelling fellow at the Endo-Klinik in Hamburg, Germany (Figure 1). The unit itself was set up in 1976 and is celebrating 40 years of existence this year. More than 140,000 total joint replacements have been implanted since the unit's inception with 7,000 patients from Germany and abroad visiting for treatment every year. I was joined by travelling fellows from Canada, India and Belgium during my time in the unit (May 2016), all under the tutelage of Dr Akos Zahar (a leading surgeon in the management of prosthetic joint infection (PJI).

A typical day starts at 7.10am with a meeting in a seminar room with a large image projector where the consultant surgeons, residents, and fellows attend. The images from the previous day's operating are reviewed and complex cases that are planned for the day are discussed. A majority of the x-rays reviewed are in a business like manner but if there are any issues then there is a discussion led by Professor Gehrke (chief of the department) and any surgeons or residents involved in the case contribute.

Figure 1

Tosan Okoro at the Endo-Klinik in Hamburg.



There were a total of 8 theatres in the orthopaedic theatre suite unit with 2 dedicated to the surgical management of PJI. Each of the 8 theatres had an average of 4 surgical cases per day. 4 theatres were combined in an open plan fashion in a single suite.

In my time in Germany, I was a 2nd or 3rd assistant in a total of 20 cases. I was able to see 11 arthroplasty revisions (3 for infection (single stage revision), 6 for aseptic loosening (4 for acetabular component revision, 2 revisions of primary knee replacements to hinged prostheses), and 2 for peri-prosthetic fractures of total hip replacement), a well as 6 primary joint replacements (5 hips and 1 knee).

Patients with infected prostheses were typically admitted 2 days before planned surgery having had an extensive preoperative work up including an aspiration of the involved hip to look for a causative organism. Patients are referred from across Europe with a typical surgical waiting time of 5 weeks [1]. A combined post-operative antibiotic regimen (local (bone cement) and systemic therapy) was always agreed in conjunction with a consultant microbiologist. There was an emphasis on surgical radical and thorough debridement of the infected cases down to clean healthy bone and soft tissue before implantation of the revision prosthesis.

The preparation of asepsis starts in the changing room- a separate room is used for changing into scrubs and even a toilet break requires removal of scrubs and changing again. A special effort is made to isolate the 2 theatres used for sepsis with a common area which has doors that shut sequentially from outside in. The positioning of the patient is done uniformly in the anaesthetic room with the preparation of the skin done by one of the surgeons in the theatre with just the gloves worn after hand washing. Draping of the patient is performed with the use of the under glove and the over-glove is only put on when surgery is due to start. Radical debridement is then performed along with explantation of the infected prosthesis with tissue samples collected for microbiology. Following thorough debridement and explantation of the infected prosthesis: the surgical bed is considered 'clean' and all gloves and drapes are changed before insertion of the new cemented prosthesis. I observed the use of a cemented modular MP Reconstruction prosthesis (Link, Hamburg, Germany) for the treatment of infected hip arthroplasty. In cases of severe proximal femoral bone loss after debridement and use of the MP Reconstruction prosthesis, an extra-osseous cement mantle is created with the chosen antibiotic regime for more effective local control of infection for the proximal part of the implant.

With regards to acetabular defects, I was able to observe different strategies of dealing with this, from the use of impaction bone grafting with tantalum augments and a cemented cup to use of a custom made implant in a case of severe acetabular bone loss with protrusio. The Endo Klinik has published their technique and results of the former method [2], with the implant removed in this instance being an Autophor ceramic acetabular cup (Osteo AG, Selzach, Switzerland) from the 1970s (Figure 2). Femoral heads for impaction grafting were prepared by cutting them in slices, and harvesting the cancellous bone as ‘croutons’, which after being placed in the defect, are reamed in, for a uniform surface to place the tantalum augment.

Figure 2.
An explanted Autophor ceramic acetabular cup (Osteo AG, Selzach, Switzerland)

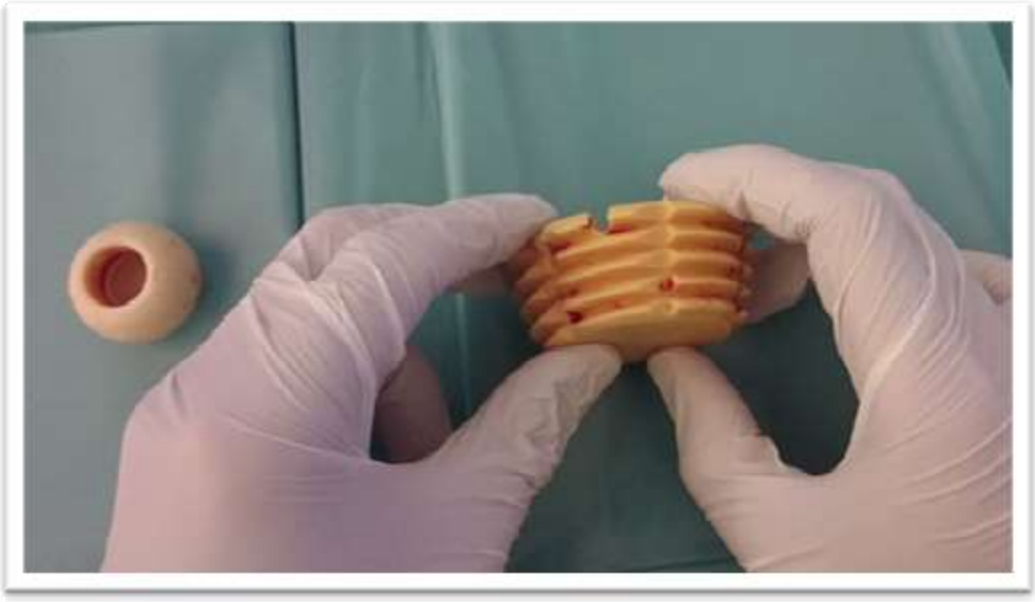

I was fortunate to go on a tour of the Links factory (Figure 3). This was located on the outskirts of Hamburg and the longstanding relationship between the Endo-Klinik and the Link Orthopaedics Company was demonstrated to us travelling fellows. It was a truly educational experience observing the process of fabrication and finishing of the implants used daily around the world. There has been a very close relationship between Link Orthopaedics and the Endo-Klinik in Hamburg with the development of prostheses used in the hip and knee arthroplasty, with the first hip replacement prosthesis (the St Georg.) developed by Walderman Link after discussions with Professor Buchholz the founder of the Endo-Klinik. Professor Buchholz had just returned from visiting John Charnley in the UK and was hoping to try new materials for hip prostheses [1]. This relationship has meant that in treating severe defects in the acetabulum and femur whilst managing PJI, surgeons at the Endo-Klinik have been able to influence the development of prostheses, which are readily available. The Endo-Klinik deals with ~400 PJIs per year and have strict rules on surgical hygiene with infection rates after primary arthroplasty of between 0.2 to 0.3% [1]. There is a valid argument for patients with PJI to be treated in specialist units, which adhere to strict protocols and policies in order to ensure a consistent and successful outcome for the patient. In the UK, PJIs tend to be managed by the operating surgeon in the first instance and referred on for further intervention in a tertiary center if this is unsuccessful. The predominant practice in the UK is for 2-stage revision for PJIs with re-infection rates of 9-20% whilst in a specialist centres like the Endo-Klinik the re-infection rates for single stage revision is ~10% at 10 years [3].

Figure 3.
Tosan Okoro visiting the Link Factory on the outskirts of Hamburg



I spent a day during my stay in the ward dedicated to the treatment of PJIs. In a twice-weekly ward round, a consultant surgeon, microbiologist, physiotherapist, occupational therapist, nursing staff and residents are all in attendance. A true multidisciplinary approach is taken to the care of the patients and I discovered during this round that the antibiotic therapy is only continued for a maximum of 3 weeks postoperatively intravenously with no conversion to oral antibiotics thought necessary as in the norm in the UK for a further period.

Hamburg is a beautiful city with a rich history. I took time out during my stay to visit several landmarks including the Lake in the city centre, St Michael's church with its panoramic views, as well as used the Harbour ferry to Finkenwender, taking in plenty of the sights along the way.

I thoroughly enjoyed the educational experience afforded me by the BOA for this travelling fellowship and I am very grateful for the opportunity.

REFERENCES

1. DirectLINK®. Magazine for Arthroplasty. Issue: September 2014. URL: http://linknederland.nl/_cache/link/media/qjvlxp1248/DirectLINK_20_01_2014.pdf. Accessed June 5, 2016
2. Gehrke T1, Bangert Y, Schwantes B, Gebauer M, Kendoff D. Acetabular revision in THA using tantalum augments combined with impaction bone grafting. Hip Int. 2013 Jul-Aug;23(4):359-65.
3. Zahar A, Gehrke TA. One-Stage Revision for Infected Total Hip Arthroplasty. Orthop Clin North Am. 2016 Jan; 47(1):11-8.