



Amy Firth is the current Hip and Knee Arthroplasty Fellow at the Nottingham Elective Orthopaedic unit. Amy gained her undergraduate honours degree in Biochemistry prior to completing Medicine at the University of Nottingham. She is a member of the British Hip Society, a National Health and Care Research (NIHR) Co-PI, past EDI representative for the East Midlands North Orthopaedic Rotation (EMNOR) training committee and Faculty of the Chesterfield, Sheffield & Derby FRCS Clinical Examination Course.



Andrew Manktelow is a Consultant Orthopaedic Surgeon working within Nottingham University Hospitals NHS Trust, with a specialist interest in primary and revision hip surgery. A past President of the British Hip Society, Andrew was re-elected to the BOA Council in 2023. Contributing to the Orthopaedic Committee Andrew reports to BOA Council on matters relevant to the Independent Sector.

Hip resurfacing: Where are we in 2025?

Amy Firth and Andrew Manktelow

Given recent history, it's a surprise to look back and think that in 2006, 10% of all hip replacements performed in the UK were hip resurfacing arthroplasties (HRAs)¹. As the popularity of metal on metal (MoM) HRAs increased there was a similar increase in the number of large diameter MoM total hip replacements (LD MoM THRs) performed, when femoral anatomy was less favourable or when the surgical exposure was felt to be challenging. The LD MoM THR concept combined the theoretical advantages of a reduced wear rate with a MoM bearing and reduced dislocation with larger head size. Unfortunately, what happened next was a major issue for our patients and for wider hip arthroplasty. Patients experienced increased failure rates, with some patients requiring complex revision surgery with poor outcomes, increased complications and re-revision rates. The catastrophic nature of some of the failures triggered huge national and international concern. This resulted in the withdrawal of LD MoM THR bearings and the demise of a number of failing MoM HRA components.

Subsequently, over time, we learned much regarding the failure of MoM bearings. In HRA the clinical significance of poor designs with reduced articulating arcs became apparent. Registry and published outcome data demonstrated the clinical relevance of component size and orientation, with larger heads and an articulation that minimised edge loading proving beneficial. Poorer outcomes were shown in women and in older patients. The attention and detailed evaluation led to a better understanding of the clinical indications and the technical challenges of HRA. Away from HRA we learned of the significance of trunnion wear, with CoCr sleeves implanted as part of a LD MoM THR². A clinical spectrum of abnormal reaction to metal debris (ARMD) was observed with varying amounts of soft tissue and bone damage associated with a varying elevation of whole blood Cobalt and Chromium ion levels. LD MoM THRs were the major

culprits alongside poorly positioned and poorly designed HRAs. As such, we learned that all HRA implants were not the same. Similarly, that HRA outcomes were very sensitive to component orientation confirmed that HRA is not an easy procedure. HRA requires an increased exposure and release. The proximal femur must be delivered in an orientation to facilitate head preparation in accurate alignment and then translated anteriorly, with the posterior approach, allowing clear access to the acetabulum to achieve sound socket fixation, in an uncemented component, without screws and in a satisfactory orientation. Many HRAs are performed in young, active patients, often muscle-bound athletic males, further challenging the surgeon to achieve optimal component orientation.

The demise of MoM bearings and the technical challenge of HRA led to a huge reduction in the number HRAs performed and the number of surgeons offering the procedure. HRA had reduced to around 1% of THRs by 2012/13¹. That number has changed very little to the present. HRA has varied in popularity worldwide. HRA was not a common procedure in the US, however at one stage it was estimated that 30% of THRs used MoM bearings. In Australia, where HRA was popular, the Australian Orthopaedic Association National Joint Replacement Registry (AOANJRR) data shows a similar reduction with the most recent data echoing a similar frequency at around 1% of THRs³. Worldwide the vast majority of HRAs performed today are in young males, with a femoral head size greater than 50mm.

Against this background, it is important to recognise that both published literature and registry data has shown reassuring outcomes for MoM HRA, when performed by experienced surgeons, with accurate component alignment and in appropriate individuals. Looking at the two existing MoM HRAs still implanted (the Birmingham Hip Resurfacing (BHR) Smith & Nephew, and the

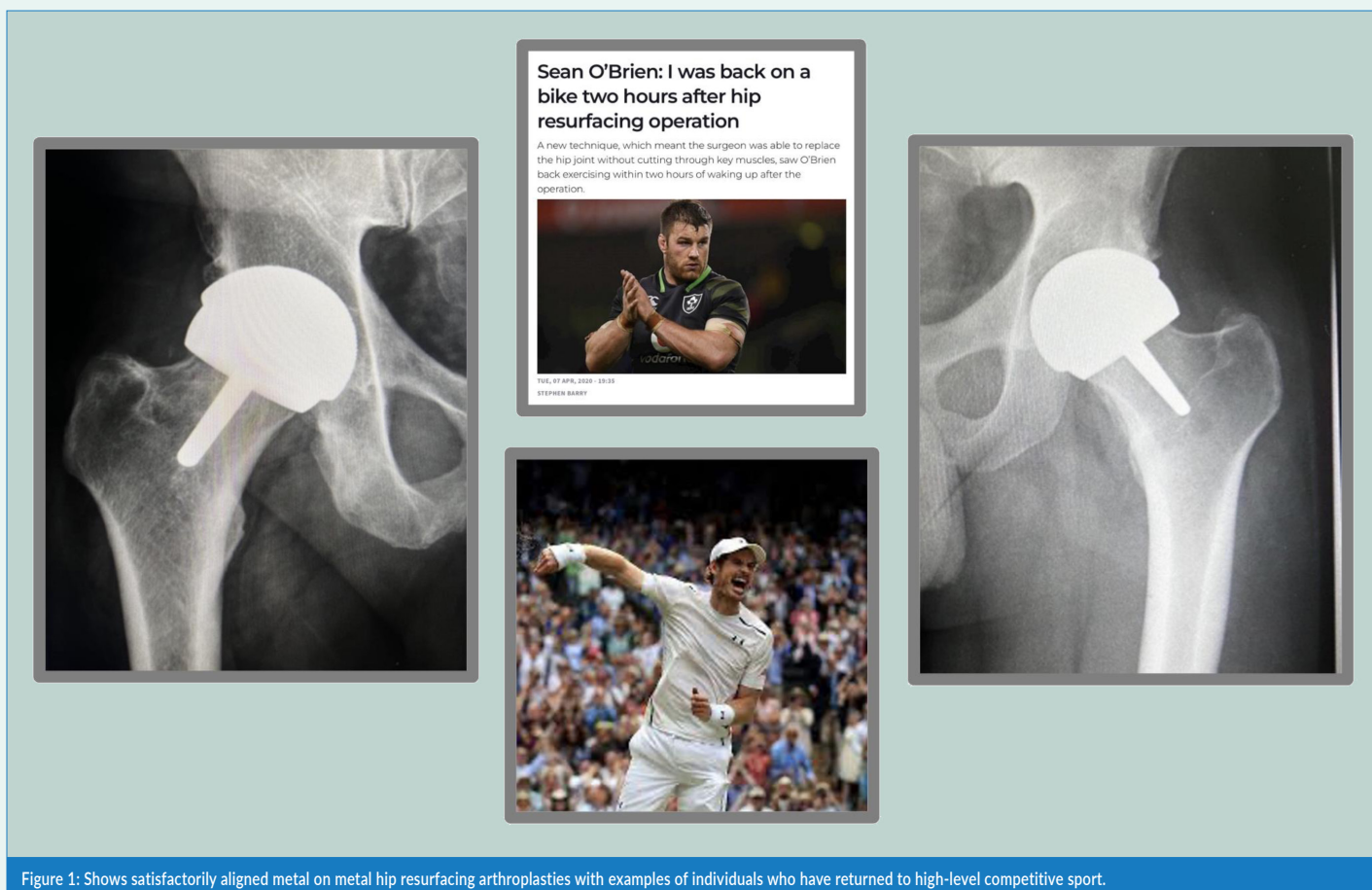

Figure 1: Shows satisfactorily aligned metal on metal hip resurfacing arthroplasties with examples of individuals who have returned to high-level competitive sport.

Adept, MatOrtho), survivorship in appropriate patients in both the NJR and AOANJRR, compares favourably with similar younger patients undergoing more traditional THR. In the UK, NJR survival rates of around 10% at 15 years and 12% at 20 years are reported. Many have suggested that HRA patients are atypical. Many have increased, and some extreme, activity requirements. There are examples of professional sportsmen, in tennis, rugby and cycling, returning to high-level performance post HRA surgery.

It is important to recognise that clinical outcomes, expressed simply as survivorship, are no longer the only goal in hip arthroplasty surgery. There have been many recent developments in THA surgery. Better bearings, implanted after enhanced functional planning, with enhanced accuracy to improve biomechanics, coupled with more conservative approaches and enhanced recovery, are all aimed at improving function and returning patients to a better activity levels than were possible historically. The question remains – can HRA deliver a functional advantage?

When looking to investigate any beneficial effect of HRA over THA, existing scoring systems can be limited by a 'ceiling effect', with THA patients providing reassuringly high post-operative scores. Anecdotal stories of HRA patients returning to a higher level

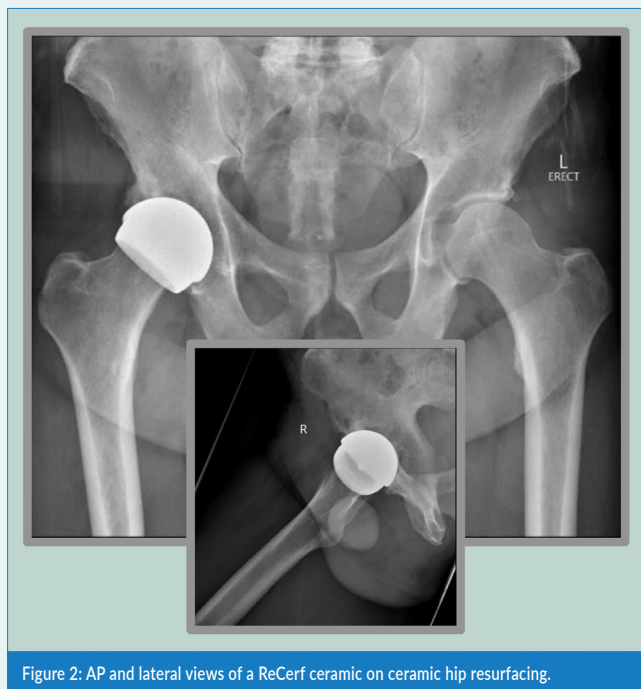of impact activities and sport, with higher demand occupational activities are hard to ignore. Looking at the literature, direct or indirect bias in what is published is hard to escape. Theoretical advantages of HRA include a significantly reduced dislocation rate, obviously a benefit to the higher demand activity groups. Preservation of femoral bone stock is demonstrable, however the benefit of a more physiological loading of the proximal femur is more difficult to demonstrate. Studies have shown that HRA patients walk better, faster and with a more normal gait pattern than those who have had a more traditional THA⁴. Studies have suggested that patients who have had both an HRA and a traditional THA, prefer their HRA⁵. There is evidence that more HRA patients return to sport⁶. Historical papers have shown patients perceive less leg length discrepancy, less thigh pain and less limp following HRA when compared to THA⁷. Additional potential benefits include more straightforward revision options when an HRA fails, in the absence of clinically significant ARMD associated soft tissue or bone damage. Specific technology exists to remove the acetabular component with minimal bone loss and femoral 'revision' simply requires the excision of the femoral head that would be performed in a traditional THA. As such, a more conservative approach to the management of complications, such as peri-prosthetic fracture and prosthetic joint

infection (PJI) could provide a theoretical advantage. Significantly reduced dislocation rate and less concern with leg length inequality are other attractive theoretical benefits.

In terms of where MoM HRA exists in the management of limiting hip arthritis in 2025, it could be summarised as such: There is good published and registry data in correctly selected patients, essentially males with good bone quality, relatively normal anatomy and with head size 50mm or greater (AOANJRR and UKNJR)⁸. In that group, many patients remain happy and active with no obvious clinical concerns, good function, with metal ions under review. However, with existing technologies, we are unable to offer HRA to females or men with small hips. Fewer surgeons have or are gaining the experience and skills required to perform HRA. Therefore, the question is, can we provide similar outcomes without the insecurities and resources involved in the monitoring of MoM HRA?

What is the future of hip resurfacing?

There have been recent developments in bearing surface options in HRA. The use of metal on polyethylene HRA (MoP HRA), has been developed and trialled in Birmingham, with PolyMotion (JointMedica). The design has evolved over a nine-year period and is currently being evaluated, in men and >>



has been implanted 250 times with a longest follow up of six-years. As of yet unpublished data shows a survivorship of 96% at six years with encouraging and consistent improvements in patient reported outcome measures (PROMS). The ReCerf CoC HRA, developed by a multinational group within MatOrtho, has been implanted in over 1,300 patients worldwide, by 21 surgeons in 26 hospitals with similarly encouraging survivorship with up to six-year follow up. 40% were in females and many with smaller hips. Many of the revisions of CoC HRA have been required for peri-prosthetic femoral

women, within a United States Food and Drug Administration (US FDA) supervised Investigational Device Exemption (IDE) study, with results available early 2027.

Ceramic on ceramic hip resurfacing (CoC HRA) has been explored as an option to deliver the benefits of HRA with an alternative bearing. CoC HRAs have been developed both by the Imperial College group, with the H1 hip resurfacing arthroplasty, an uncemented device and by MatOrtho, with the ReCerf ceramic hip resurfacing. The ReCerf, is based on the Orthopaedic Data Evaluation Panel (ODEP) 15A rated Adept MoM HRA, with similar hybrid fixation. Recent presentations and publications have shown promising early experience in this area.

The H1 uncemented CoC HRA, developed by Professor Cobb at Imperial College London

neck fracture, which could indicate poor patient selection or concerns with surgical technique rather than specific concerns with the CoC bearing. In a British Hip Society (BHS) presentation in 2025, female sex and small component size, (two major limitations of MoM HRA) were reassuringly shown to have no adverse effect on outcome with the ReCerf device.

While early experience with both CoC HRA and MoP HRA are encouraging, it is essential that the lessons of the past are not forgotten. Future practice will involve a careful evaluation of new technologies alongside established MoM HRA data. We will need to investigate and define the indications for HRA. A more detailed evaluation and understanding of any functional and outcome benefits of HRA over THA is essential. Other possible benefits in terms of ease of revision, conservative management of complications and the bone stock implications on both the femoral and acetabular side must be considered. The use of enhanced planning, instrumentation and robotics should be considered to reduce any 'learning curve' and ensure accurate and appropriate component orientation. Surgeon education, including the challenge of exposure will be crucial. It is important that we understand what can be delivered reliably against patient expectation.

Hip resurfacing should remain an option for patients with hip arthritis that limits quality of life, compromising required occupational and desired recreational activities. In the introduction of any new and potentially exciting bearing option, we must learn from previous experience. We must work to deliver a step wise, controlled and carefully evaluated introduction, ensuring patients are not harmed as we strive to improve outcomes. Within that process and if recent positive reports are fulfilled, HRA may yet have a bright future. ■

References

1. Achakri H, Ben-Shlomo Y, Blom A. National Joint Registry 21st Annual Report 2024 [Internet]. National Joint Registry; 2023. Available from: https://reports.njrcentre.org.uk/Portals/0/PDFdownloads/NJR%2021st%20Annual%20Report%202024_Hips.pdf.
2. MacDonald DW, Chen AF, Lee GC, Klein GR, Mont MA, Kurtz SM, et al. Fretting and Corrosion Damage in Taper Adapter Sleeves for Ceramic Heads: A Retrieval Study. *J Arthroplasty*. 2017;32(9):2887-91.
3. AOANJRR Annual Report 2024 [Internet]. Australian Orthopaedic Association National Joint Replacement Registry; 2024. Available from: <https://aoanjrr.sahmri.com/annual-reports-2024>.
4. Aqil A, Drabu R, Bergmann JH, Masjedi M, Manning V, Andrews B, et al. The gait of patients with one resurfacing and one replacement hip: a single blinded controlled study. *Int Orthop*. 2013;37(5):795-801.
5. Calkins TE, Suleiman LI, Culvern C, Alazzawi S, Kazarian GS, Barrack RL, et al. Hip resurfacing arthroplasty and total hip arthroplasty in the same patient: which do they prefer? *HIP Int*. 2021;31(3):328-34.
6. Magan A, Wignadasan W, Kayani B, Radhakrishnan G, Ronca F, Haddad FS. A meta-analysis assessing time for return to sport following hip resurfacing. *Arch Orthop Trauma Surg*. 2022;143(6):3575-85.
7. Barrack RL, Ruh EL, Berend ME, Della Valle CJ, Engh AC, Parvizi J, et al. Do Young, Active Patients Perceive Advantages After Surface Replacement Compared to Cementless Total Hip Arthroplasty? *Clin Orthop*. 2013;471(12):3803-13.
8. Van Der Straeten C, Gross TP, Amstutz H, Brooks PJ, Samuel LT, Su EP, et al. Hip resurfacing arthroplasty in young patients: international high-volume centres' report on the outcome of 11,382 metal-on-metal hip resurfacing arthroplasties in patients ≤50 years at surgery. *HIP Int*. 2022;32(3):353-62.




Figure 3: 60-year old male medical colleague and a 50-year old female enjoying high level recreational activities post ceramic on ceramic hip resurfacing.