British Orthopaedic Travelling Fellowship Award (ZimmerBiomet - Trauma)
Derek Cawley FRCS Orth

I would firstly like to extend my gratitude to the British Orthopaedic Society and ZimmerBiomet for providing this award. It was truly appreciated. I travelled to Switzerland for two weeks during December 2016 to visit two busy centres- CHUV, Lausanne and Schulthess Clinic, Zurich. I was hosted by Dr John Duff MD at the former and Dr Deszo Jeszenszky MD at the latter. I met the spinal teams at both centres including Dr Victor Bartanusz, Prof. Roy Daniel at CHUV Lausanne and Dr Tamas Fekete, Dr Daniel Haschtmann, Dr Frank Kleinstück at Schulthess Clinic. I was warmly received and I am very grateful to them.

My primary interest is in spinal surgery and I travelled to Switzerland while on fellowship to see and learn techniques that I have not had as much exposure to previously. Like Ireland where I have trained as an orthopaedic surgeon, there is an increasing prevalence of elderly patients with pathologic fractures from osteoporosis or from metastatic tumor, both conditions disproportionately affecting the vertebral column. I had a superb exposure to complex spinal pathology and procedures. The health system in Switzerland is highly organised with efficient access to imaging techniques and inter-speciality referral. Both hospitals are quite different- the CHUV Lausanne is a publically funded university hospital while the Schulthess Clinic is a foundation-based hospital. Both institutions have strong academic records and I partook in the morning meetings which included local research, discussion of complex cases and training of junior trainees. Unlike in Ireland, the spinal unit at both centres had a mix of both orthopaedic and neurological surgeons which conferred the benefit of different training backgrounds and perspectives on addressing spinal pathology.

Some of the procedures I saw are not performed in most spinal centres such as C1C2 interbody cage insertion. Other procedures that I saw were being performed by the surgeons who first described them in the literature such as trans-foraminal lumbar interbody fusion and cemented pedicle screw insertion. Despite cutting edge technology and techniques, I still observed the occurrence and management of problems that haunt all spine surgeons such as infected prostheses, adjacent segment degeneration and post-operative neurological deficit.

While I have gained a lot of knowledge from my reading and experience, visitation to specialised units is a worthwhile exercise as described. There are many details to one's learning that are not readily available in published literature that one can learn- particularly through observation and through informal discussion.

Below are some cases that I found very interesting.

A Teenager with Down's Syndrome had presented with recurrent fainting episodes. She had a diagnosis of atlantoaxial instability. Surgical stabilisation of the C1C2 joint was undertaken. This involved the aid of intra-operative CT scanning to guide screw placement (O-arm). While not entirely necessary, the added CT navigation was particularly helpful in this case as the osseus anatomy was not normal. While screw insertion at C2 would normally be placed in the pars intra-articularis, it was placed intra-laminar instead. Trans-articular cages with autogenous bone graft were also placed between C1C2. Again, the orientation of the facets at this level were reversed and placement of the cages was helped by the O-arm.



Figure: Lateral view radiograph post C1C2 fusion

A young man was previously treated conservatively for a Jefferson fracture, a burst fracture of the C1 vertebra. Most of these fractures are conservatively treated and heal in a reasonable alignment, follow up CT scanning demonstrated a late lateral migration of the right side lateral mass of the C1 ring. There was persistent associated neck pain and stiffness. Fixation was recommended and the patient had insertion of posterior based pedicle screws at C1, linked to pars screws at C2. A cross-connector is normally only used with long posterior constructs but in this case, was used to achieve partial realignment of the C1 ring and preservation of the medio-lateral integrity of the construct.

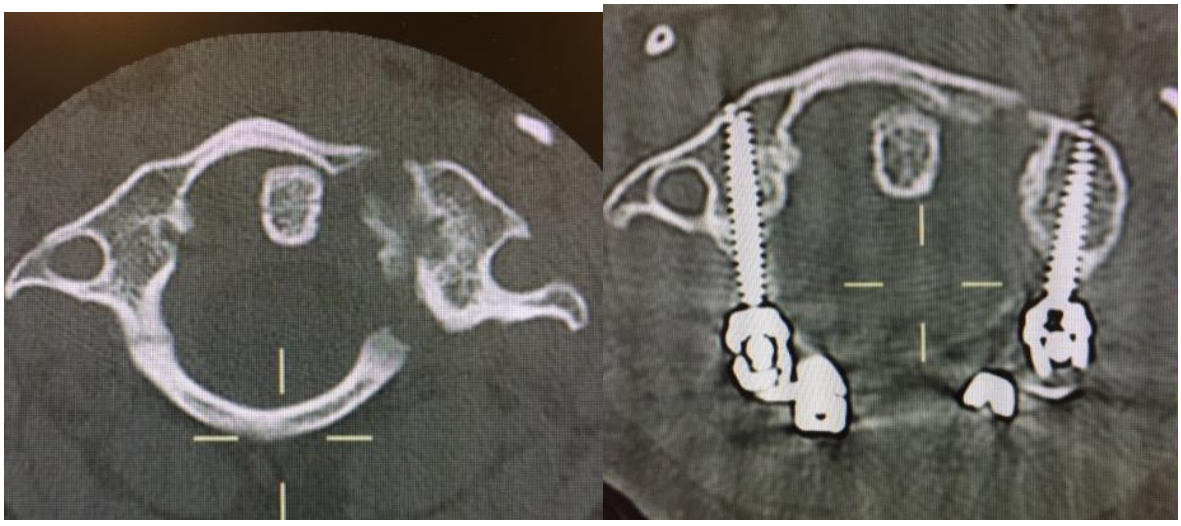

Figure: Pre- and Post-operative CT scans with delayed union C1 fracture with fixation

A young man previously had occipitocervical fixation for a fracture at C2 which resulted in dropped-head syndrome. This was because of loss of extensor muscle activation posteriorly with the dissection of muscle attachments off C2 spinous process. Once healed this construct was removed with posterior cervical instrumentation and anterior expandable cage insertion.

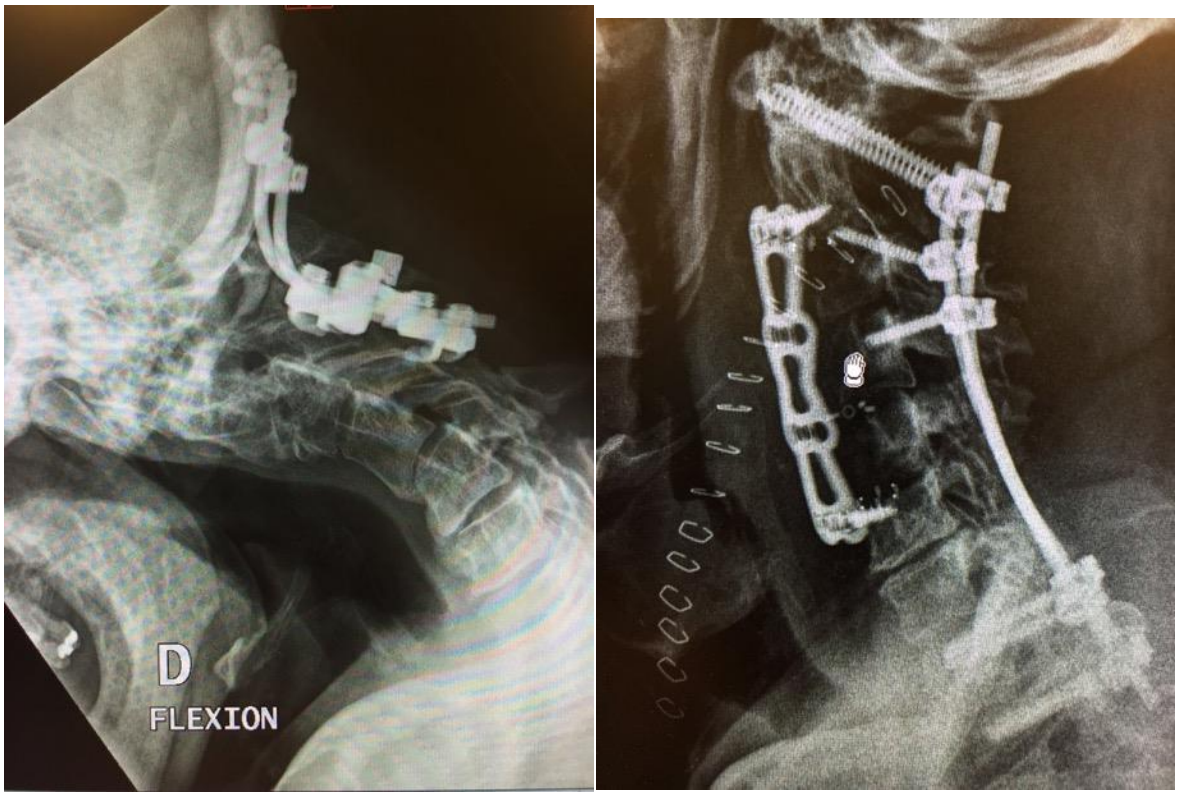

Figure: Pre- and Post-operative radiographs demonstrating occipito-cervical fixation with dropped-head syndrome and subsequent fixation.

An elderly man had a short history of metastatic melanoma and a partially stabilised cervico-thoracic junction. Immunotherapy is starting to demonstrate satisfactory results in melanoma management with potential for increasing prevalence of spinal metastatic cancer.

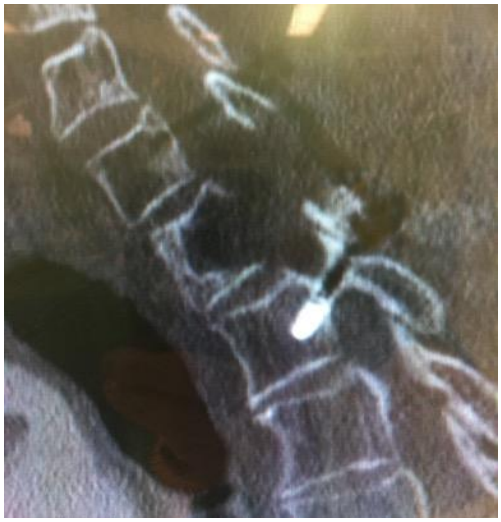

Figure: Pre-operative radiograph with melanoma lytic lesion.

A young man with a C7T1 prominent disc and neuropathic dermatomal pain had a minimally invasive posterior foraminotomy. The tube system was used with the microscope. This system is ideal for muscle preservation, lower dissection and therefore, post-operative pain, shorter length of hospital stay and earlier return to work. The posterior approach also allowed preservation of the cervical disc and therefore no indication to fuse.

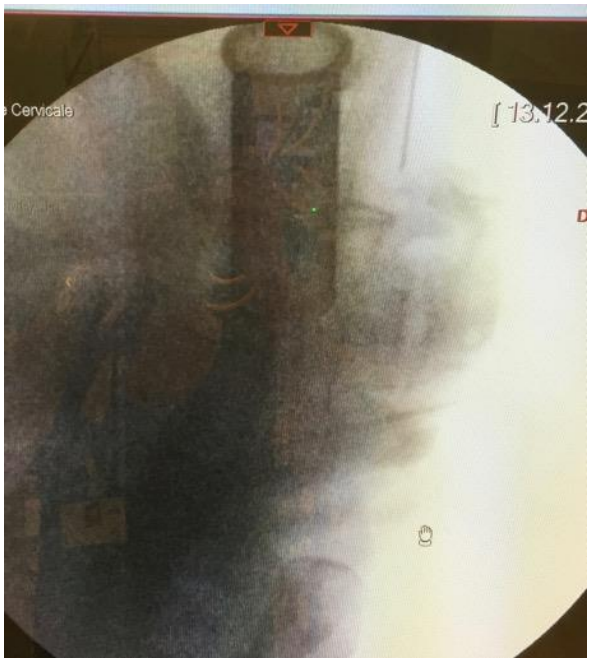

Figure: Intra-operative radiograph demonstrating placement of working tube for posterior foraminotomy for cervical disc herniation

An elderly lady had previously a T9 to Iliac crest fixation. Because of the stiff spinal construct and osteoporotic kyphotic progression, she had a fracture at T8, the junction of the previous fixation, thus presented with multifocal back pain. She had also two pseudo-arthroses which included the exchange of pedicle screws for larger ones, revision of her previous TLIF and proximal extension of her fixation to include cement-augmented pedicle screws.

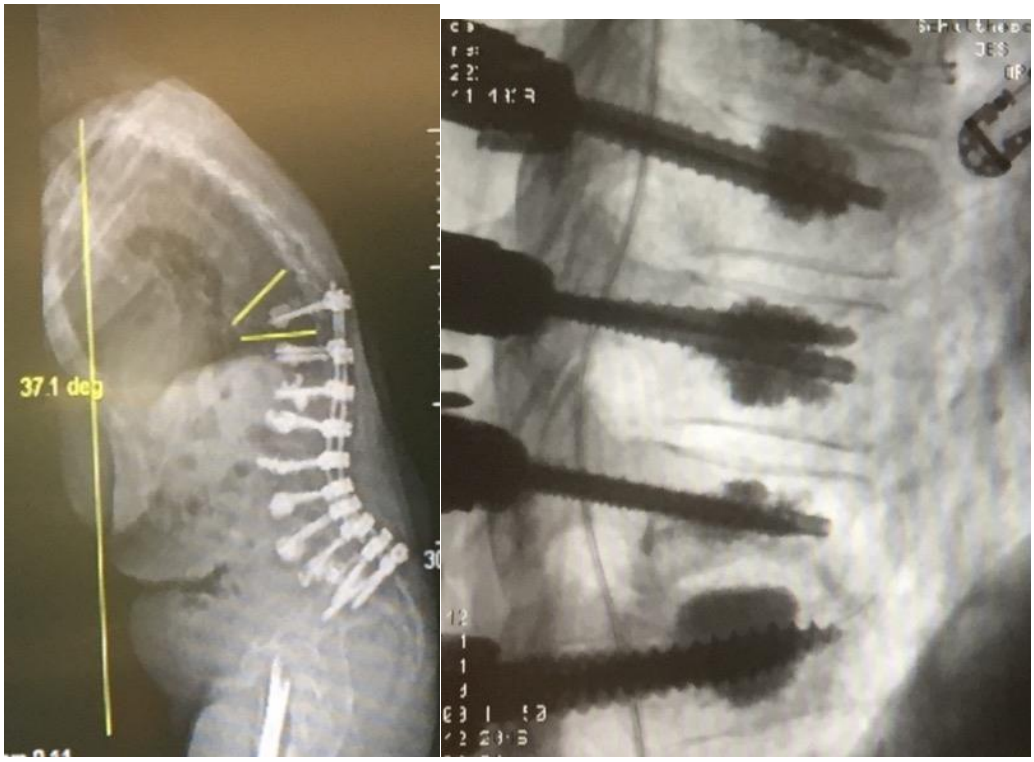

Figure: Pre-operative standing radiograph with previous fixation, proximal fracture with kyphosis, previous hip fracture